

# HIP DYSPLASIA

## OSTEOARTHRITIS OF THE HIP JOINTS IN DOGS

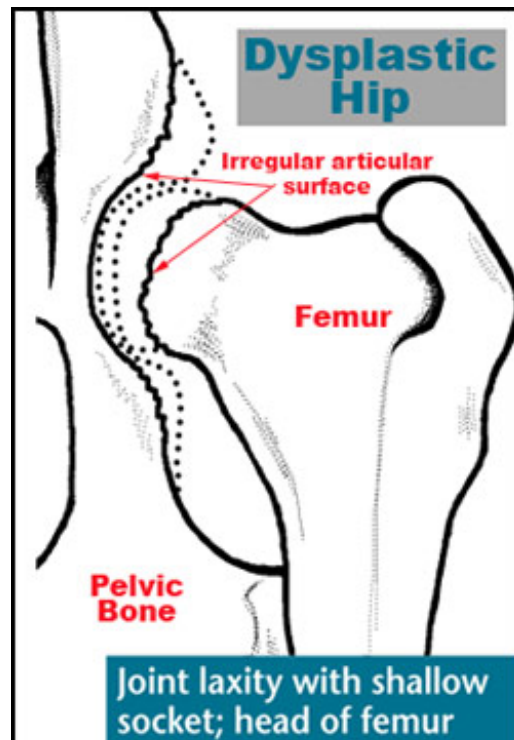


Hip dysplasia results from the abnormal development of the hip joint in the young dog. It is brought about by the laxity of the muscles, connective tissue, and ligaments that should support the joint.

Boris, a German Shepherd, was diagnosed with hip dysplasia at four months of age. Boris' breeder didn't want to give the dog to a family that would have to deal with expensive surgery later on in the dog's life. She considered euthanasia, but then found someone who understood the breed and problems, and was willing to make sure that the puppy had the best chance he could.

Most dysplastic dogs are born with normal hips, but due to genetics, nutrition, growth rate, stress on the joints, and possibly other factors, the soft tissues that surround the joint develop abnormally as the puppy grows. This causes less support of the joint and joint instability, allowing the bones of the joint to move apart. Changes then occur in the surfaces of the bones, which lead to painful arthritis.

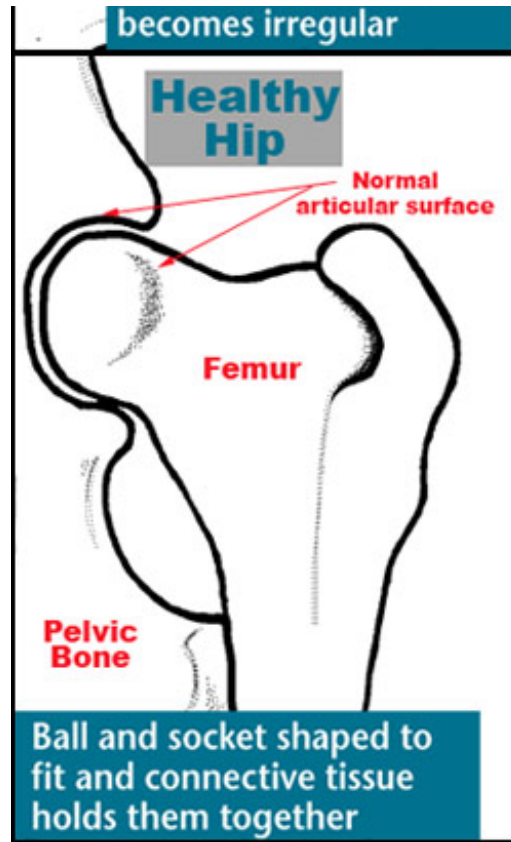
Boris' new owner, Sue, knew that regular moderate exercise (no jumping) would help build up the muscles around his diseased joints and that a premium, healthy [diet](#) and eliminating table snacks would keep his weight down and put less stress on his joints. Boris' vet also suggested adding a product containing glucosamine and chondroitin, to support healthy cartilage and synovial fluid, and including a product with omega-3 fatty acids,



which further support joint health. Sue decided to try [Joint Care 2 with MSM](#), along with our [Omega-3 Fatty Acid Soft Chews](#).

At three years of age Boris was still going strong and keeping slim at 105 lbs. Although he didn't play quite as hard as his canine housemates, he was certainly no couch potato. He was regularly weighed at the veterinarian's office and was doing well.

Later on in Boris' life, Sue became lax about giving him over-the-counter glucosamine products and watching his food intake. She couldn't see the changes in Boris, but friends noticed that he was having real trouble going up the stairs and expressed their concern to Sue, who took him in to the veterinarian right away. Surprisingly, Boris had gained over 20 lbs! The veterinarian prescribed a non-steroidal antiinflammatory (NSAID), [Rimadyl](#) (carprofen), and put him on a strict diet. Within two months he was nearer to his 105-lb weight and showed some improvement in his ability to move around and climb stairs.



Some dogs are not as lucky as Boris. Even Boris may not be so fortunate in the future if the changes in his hips become so severe he has difficulty in getting up and walking. Then, surgery may be the only option. He may require total hip replacement if the prophylactic measures are not successful.

### Surgical Options for Hip Dysplasia

Several different surgical options for dogs with hip dysplasia exist, depending on the age and weight of the dog, and the severity of the joint degeneration.

#### Triple Pelvic Osteotomy (TPO)

This procedure is used in young dogs, usually less than 18 months of age, whose x-rays show loose hip joints, and who have not developed severe damage to the joints. The procedure involves a surgical breaking of the pelvic bones and a realignment of the head of the femur in the socket, correcting the loose joint. This is a major surgery, but has been very successful on animals that meet the requirements.

#### Total Hip Replacement (THR)

The most radical of the surgeries, THR involves removing the existing joint and replacing it with a prosthesis. A candidate for THR must be skeletally mature and usually must weigh over 20 pounds. If both hips need replacing, usually 3 months must pass between the surgeries. This procedure is very expensive but produces a functionally normal joint, eliminates degenerative changes, and alleviates joint pain. This is a surgery that Boris may require later on in life if the prophylactic measures don't work.

#### Femoral Head and Neck Excision (Ostectomy)

This procedure may be recommended for very active dogs or smaller dogs, usually less than 45 lbs, but it may be successfully performed on larger dogs. In this procedure, the head of the femur is surgically removed and a fibrous pseudo-joint forms. This procedure is used in cases where severe degenerative joint disease has occurred that cannot be managed medically and total hip replacement is not feasible. Although this will ease the pet's pain, the range of

motion and stability of the joint are decreased.

### Juvenile Pubic Symphysiodesis

This relatively new surgery is currently being evaluated. This surgery is better characterized as a preventive measure than a treatment for hip dysplasia. This surgery prematurely fuses two pelvic bones together, allowing the other pelvic bones to develop normally. This changes the angle of the hips, lessening the likelihood of arthritis. Early diagnosis is critical, since the procedure must be done before 20 weeks of age, preferably at 16 weeks.

### Pectineal Myectomy

Seldom performed anymore, this is a somewhat controversial treatment for patients with chronic hip dysplasia. The pectineus, one of the muscles attaching the femur to the pelvis, is removed and the tension on the joint is reduced. This offers some pain relief for some patients, but does not slow the progression of the disease.

### DARthroplasty

"DAR" stands for Dorsal Acetabular Rim and this procedure is fairly new and controversial. It involves taking bone grafts from other areas of the pelvis to lengthen the rim of the acetabulum, creating a deeper "socket". The best candidates for this procedure are dogs too old for TPO or that have just started developing degenerative arthritis.

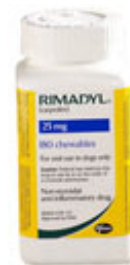## We Recommend



[Omega-3 Fatty Acid Capsules](#)



[Joint Care 2 with MSM](#)



[Rimadyl®](#)