Dental Resorption Lesions

Drs. Foster & Smith Educational Staff

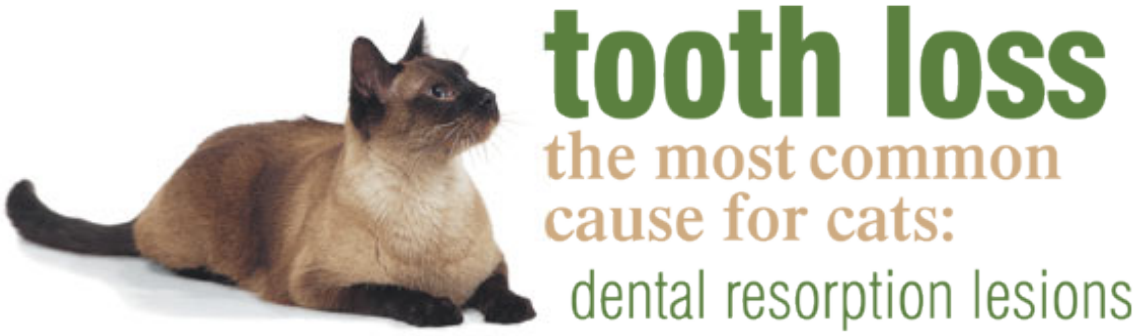

Cats are prone to a serious dental disease called 'external odontoclastic resorption lesions' (EORLs), 'cervical line lesions,' or 'neck lesions.' This is the most common disease in feline dentistry. Various studies have found 28-67% of cats have resorption lesions. They are the most common cause of tooth loss in the cat.

EORLs tend to occur in older cats (over 4 years of age) and may be more common in purebred cats, especially Siamese and Abyssinians.

What are dental resorption lesions?

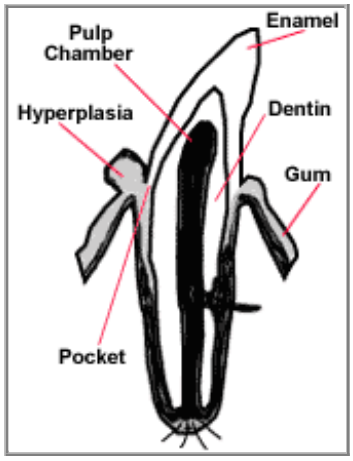

Dental resorption lesions result in the loss of tooth structure, starting with the outer enamel surface, usually at or below the gumline. The lesions, which are NOT cavities, begin as a loss of tooth enamel and can eventually spread to the dentin and then the pulp canal, which contains the blood vessels and nerves to the tooth. Sometimes, the entire crown of the tooth may be missing.

Resorption lesions are progressive and may be singular or multiple and on the lingual (side where the tongue is) or buccal (side where the cheek is) side of the tooth. Some lesions are readily apparent and others may be hidden under areas of plaque or swollen gums. This is why a cat needs to be anesthetized to determine if such lesions are present: the entire surface of each tooth must be examined.

The lesions most commonly occur in the larger, multi-rooted teeth - the molars and premolars - at the area where the roots diverge. They can also occur in the canine teeth and incisors.

What causes dental resorption lesions?

The cause of these resorption lesions is unknown. One theory is that the inflammation caused by plaque may stimulate cells called 'odontoclasts,' which eat away at the enamel of the tooth. Other possible causes include autoimmune disorders, viral diseases, or a nutritional deficiency.

What signs of disease are associated with resorption lesions?

EORLS which have eroded through the enamel may be very painful. Cats with oral pain may appear irritable or aggressive, have a change in appetite or food preference, and may have difficulty chewing and eating (food falls from their mouth). Cats with EORLs may show pain when their jaws are touched and may also have increased salivation or oral bleeding.

How are resorption lesions diagnosed?

Many lesions may be easily visible. However, a dental explorer should be used to examine each tooth above and below the surface of the gum. Any calculus on the teeth needs to be removed before a complete examination can be performed.

Dental radiographs are helpful in diagnosing this condition and evaluating the extent of disease. Resorption lesions are graded I-V according to the amount of tooth that is lost with Grade I being mild and Grade V being severe.

Classification of Feline Resorption Lesions

Stage I: Loss of enamel only, extending less than

*Unauthorized use of any images, thumbnails, illustrations, descriptions, article content, or registered trademarks of **Foster & Smith, Inc.** is strictly prohibited under copyright law. Site content, including photography, descriptions, pricing, promotions, and availability are subject to change without notice. These restrictions are necessary in order to protect not only our copyrighted intellectual property, but also the health of pets, since articles or images that are altered or edited after download could result in misinformation that may harm companion animals, aquatic life, or native species.*

How are resorption lesions treated?

Whether to attempt to restore EORLs is still controversial. Grade I lesions would be the only ones amenable to restoration, and may be treated with glass ionomer or sealants. The fluoride in these products desensitizes the area and strengthens the enamel. Restoratives will not necessarily stop the progression of the disease. Grade II-V lesions are generally not restored, but the tooth is extracted. If the EORL has destroyed a large portion of the tooth, it may break off, leaving the root behind. In these cases, the root may need to be removed.

It is recommended that cats who have a history of EORLs should have a prophylaxis (professional dental cleaning) every six months.

Home dental care for cats with EORLs includes the use of a 0.4% stannous fluoride gel applied weekly with a cat toothbrush or cotton swab. A dry diet is recommended and antibiotic therapy may be instituted.

0.5 mm into the tooth.
Stage II: Lesion extends into the dentin.
Stage III: Lesion extends into the pulp canal, but good tooth structure remains.
Stage IV: Lesion extends into the pulp canal and there is extensive loss of tooth structure.
Stage V: Crown of tooth is missing, but roots are present.

References

DeBowes, L J. Evaluation and management of Oral Disease. In August, Jr (ed.) Consultations in Feline Internal Medicine 3. W.B. Saunders Co. Philadelphia, PA; 1997;55-59.

Gengler, W. Introductory Dental Laboratory. Verona, WI; 1996.

Holstrom, SE; Frost, P; Gammon, RG. Veterinary Dental Techniques. W.B. Saunders Co. Philadelphia, PA; 1992;296.

*Unauthorized use of any images, thumbnails, illustrations, descriptions, article content, or registered trademarks of **Foster & Smith, Inc.** is strictly prohibited under copyright law. Site content, including photography, descriptions, pricing, promotions, and availability are subject to change without notice. These restrictions are necessary in order to protect not only our copyrighted intellectual property, but also the health of pets, since articles or images that are altered or edited after download could result in misinformation that may harm companion animals, aquatic life, or native species.*