Signs of Osteochondritis Dissencans

Drs. Foster & Smith Educational Staff

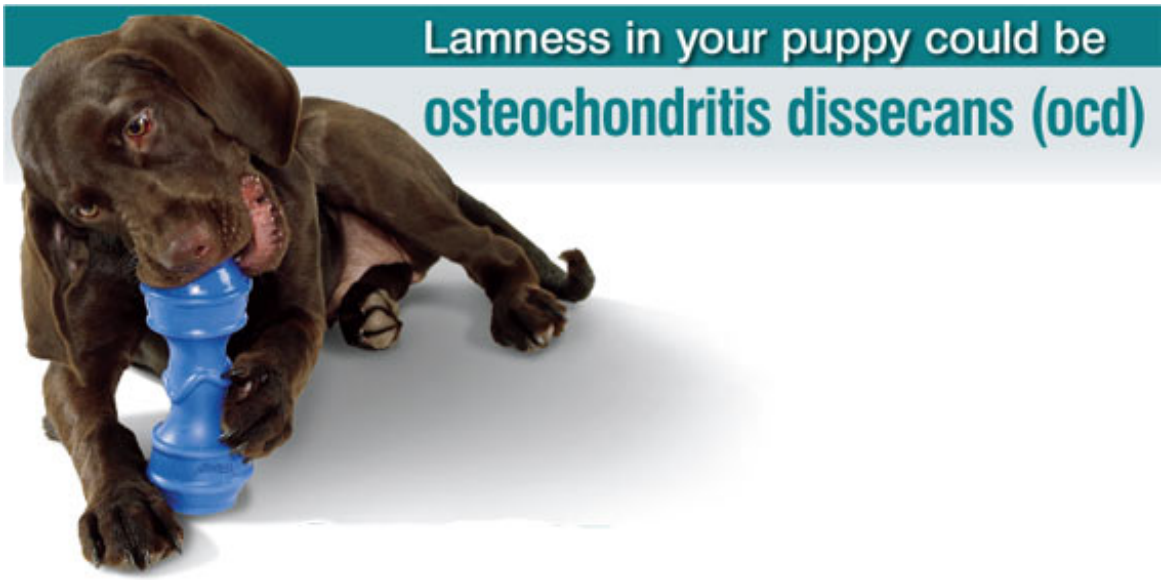

If your 4 to 10 month old large or giant breed dog is limping either slightly or severely, he may have a condition called *Osteochondritis Dissecans* or OCD. It is generally found in the shoulders, knees, elbows, or "wrists" and primarily affects the front legs. Nearly 75% of cases involve the shoulder joint.

OCD occurs when cartilage cells do not develop correctly and result in thickened areas of cartilage that separate or crack from the attached bone. Large cartilage flaps may form or small pieces of cartilage may break off and float free in the joint causing limping or reluctance to bear weight on the affected limb.

The exact cause is not known, but heredity, joint trauma, rapid growth, and poor nutrition are thought to have some bearing on the development of this condition.

Veterinarians suspect OCD when a young dog comes in with sudden, painful lameness. He will manipulate the dog's affected leg, and take an x-ray to verify the diagnosis.

Conservative treatments include cage rest with leash walks for 4 to 8 weeks in combination with medications like carprofen (Rimadyl) or other anti-inflammatories. In most cases, however, surgery is performed to remove the affected cartilage.

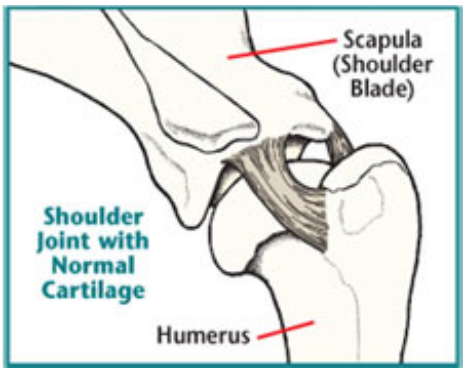

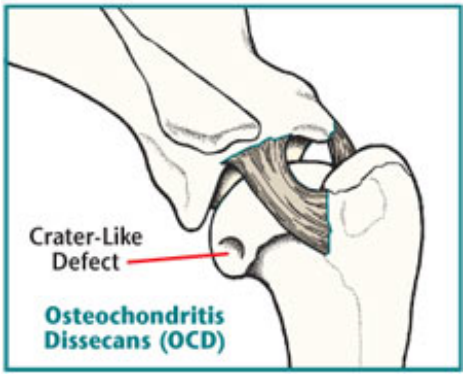

*Unauthorized use of any images, thumbnails, illustrations, descriptions, article content, or registered trademarks of **Foster & Smith, Inc.** is strictly prohibited under copyright law. Site content, including photography, descriptions, pricing, promotions, and availability are subject to change without notice. These restrictions are necessary in order to protect not only our copyrighted intellectual property, but also the health of pets, since articles or images that are altered or edited after download could result in misinformation that may harm companion animals, aquatic life, or native species.*